

## EP CASE REPORT

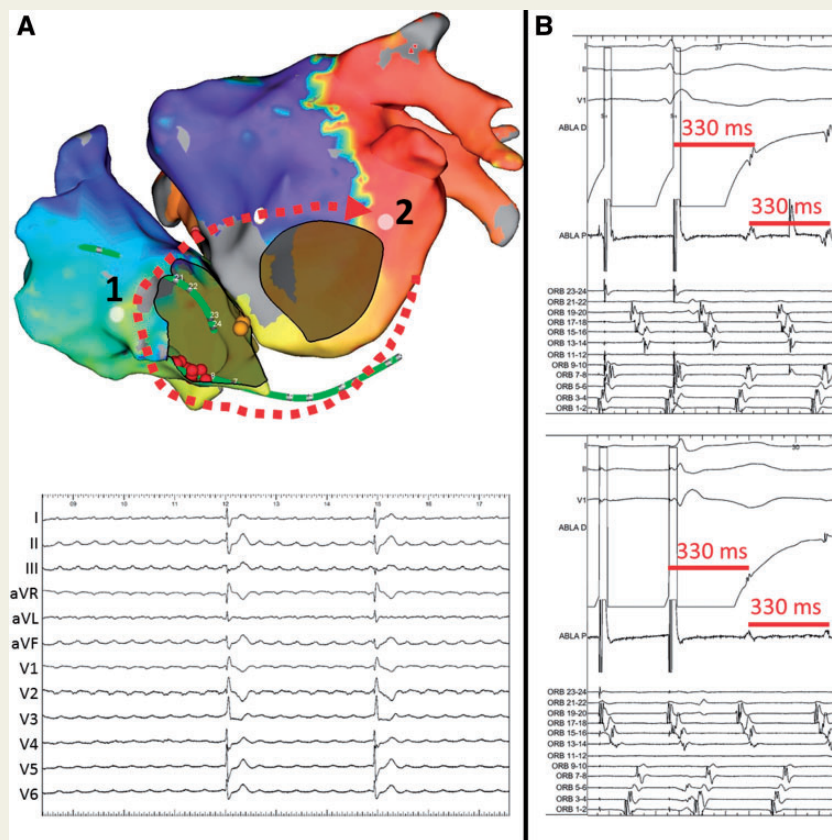
# Macroreentrant atrial tachycardia around the native common atrioventricular valve in a surgically corrected complete atrioventricular septal defect

Javier Moreno<sup>1</sup>, Eduardo Franco<sup>1\*</sup>, and Inmaculada Sánchez<sup>2</sup>

<sup>1</sup>Arrhythmia Unit, Cardiology Department, University Hospital Ramon y Cajal, Carretera de Colmenar Viejo, Km 9.100, Madrid 28034, Spain; and <sup>2</sup>Pediatric Cardiology Department, University Hospital Ramon y Cajal, Madrid, Spain

\* Corresponding author. Tel: +34913369006; fax: +34913368515. E-mail address: efranco@academiamir.com

A 32-year-old female, with a surgically corrected complete atrioventricular septal defect, developed an atrial tachycardia (Figure, ECG after adenosine in Panel A, bottom) after a mitral prosthetic valve implant. An ablation procedure was scheduled.



A 24-pole catheter (Orbiter<sup>®</sup>; Bard Medical) was placed around the right-sided part of the common atrioventricular valve with its distal part within the coronary sinus. Post-pacing intervals along the coronary sinus matched the tachycardia cycle length. Left atrial activation map (Figure, Panel A, top; EnSite<sup>™</sup> Precision<sup>™</sup> navigator) showed a clockwise rotation around the left-sided part of the common atrioventricular valve. As left atrial electrograms comprised only ~50% of the cycle length, the right atrium was also mapped. Panel B displays concealed entrainment and post-pacing intervals similar to the tachycardia cycle length, from the lateral ends of both right-sided (top) and left-sided (bottom) parts of the common atrioventricular valve (entrainment from points #1 and #2 in Panel A, respectively). With the diagnosis of macroreentrant atrial tachycardia around the native common atrioventricular valve (online supplementary video shows propagation map), a line of ablation along the theoretical cavo-tricuspid isthmus was performed (red spheres in Panel A), successfully terminating the arrhythmia.

Patients with complete atrioventricular septal defect are born with different types of a common 5-leaflet atrioventricular valve. Thus, a theoretical arrhythmia is a macroreentry around their common atrioventricular valve.

We present the case of a macroreentrant atrial tachycardia in a 32-year-old female. She was born with a complete atrioventricular (AV) septal defect, surgically corrected at the age of 9 months. During follow-up, the patient progressively developed severe mitral stenosis and, at the age of 31, she required a mitral prosthetic replacement (On-X™ Conform-X Mitral; Size 25–33). Soon after surgery, she developed an atrial tachycardia (Figure, ECG after a 12-mg adenosine bolus in Panel A, bottom). Due to its persistence, an ablation procedure was scheduled 6 months after surgery.

The study was performed in atrial tachycardia under general anaesthesia. A 24-pole catheter (Orbiter®; Bard Medical Inc.) was placed around the right-sided part of the common AV valve with its distal part within the coronary sinus. Post-pacing intervals along the coronary sinus matched the tachycardia cycle length. As such, a transeptal access was performed and a left atrial activation map was created using the EnSite™ Precision™ navigator (St Jude Medical Inc). The electroanatomical mapping (Figure, Panel A, top) showed a clockwise rotation around the left-sided part of the common AV valve and a scarred area corresponding to the surgical patch closing the ostium primum septal defect. As left atrial electrograms comprised only ~50% of all the cycle length, the right atrium was mapped and entrainment was also performed around the right-sided part of the common AV valve. Similar excellent post-pacing intervals were found, as around all the left-sided part. Panel B displays concealed entrainment and post-pacing intervals similar to the tachycardia cycle length, from the lateral ends of both right-sided (top) and left-sided (bottom) parts of the common AV valve (entrainment from points #1 and #2 in Panel A, respectively). Long post-pacing intervals were systematically obtained away from the AV valvular plane. With the diagnosis of macroreentrant atrial tachycardia around the native common AV valve (online supplementary video shows propagation map), a line of ablation along the theoretical cavo-tricuspid isthmus (CTI) was created (red spheres in Panel A), successfully terminating the arrhythmia. No recurrences have occurred after a 3-month follow-up.

A complete AV septal defect is a congenital deficiency of the AV septum due to an abnormal or insufficient fusion of the superior and inferior endocardial cushions with the atrial and ventricular septum.<sup>1</sup> Patients are born with different grades of combinations of a common 5-leaflet AV valve and atrial and ventricular septal defects. Thus, a theoretical arrhythmia in these patients is a macroreentry around their common AV valve. To the best of our knowledge, this is the first fully characterized, after extensive biatrial mapping, case in the literature. The reason might be because some apparently 'standard' macroreentries around the right-sided part of the common AV valve (resembling a cavo-tricuspid macroreentrant atrial tachycardia) found in these patients (excellent post-pacing interval at the theoretical CTI and local termination) are actually involving both parts of the common AV valve instead of just the right-sided one. The key feature in these cases would be a lack of a typical CTI-dependent ECG despite its successful termination there. Of note, in these patients the AV node is typically displaced posteriorly and inferiorly toward the coronary sinus (yellow spheres in Panel A), which may increase the risk of AV block during ablation of the theoretical CTI, if its septal portion is targeted.

**Conflict of interest:** Dr. Javier Moreno receives consulting fees from St Jude Medical. The rest of the authors declare no conflicts of interest.

## Reference

1. Craig B. Atrioventricular septal defect: from fetus to adult. *Heart* 2006;**9**:1879–85.